



PATIENT

Sam Stiles

PRESENTING CLINICAL SIGNS

History: New right-sided murmur. Assess prior to dental.

SPECIES

Canine

ELECTROCARDIOGRAPHIC FINDINGS *Note: Single lead ECGs are evaluated as a rhythm strip.

Morphology/MEA cannot be definitively commented on.

A single lead ECG is available; 50mm/s, 20mm/mV. The average heart rate is 195bpm with a largely regular rhythm. P waves cannot be seen throughout due to device insensitivity; however, a sinus origin is suspected. No ectopic beats, pauses or other dysrhythmias observed.

ECG diagnosis: Normal sinus rhythm.

BREED

Beagle Mix

SEX

Male Neutered

AGE

12 years

ECHOCARDIOGRAM FINDINGS

2D, m-mode, color flow and doppler imaging is available. Mild mitral valve leaflet thickening with no obvious prolapse into the left atrial lumen. No mitral regurgitation is identified. Normal left atrial dimension. Normal LV diameter with normal myocardial function. The tricuspid valve appears subjectively normal. No TR. The right heart is normal. No overt evidence of pulmonary arterial hypertension. The pulmonic and aortic valves are normal in morphology and mobility. No aortic abnormalities identified, with normal outflow velocity. Normal pulmonic outflow velocities. No aortic insufficiency. No pulmonic insufficiency. No pericardial or pleural effusion noted. No cardiac tumors observed.

WEIGHT

27.4lbs

CARDIAC CHART

INTERPRETED BY

Maggie Machen Lamy,
DVM, DACVIM
(Cardiology)

CANINE CARDIAC PARAMETERS	MR VMAX (m/s)	TR VMAX (m/s)	LA/AO (Boon method)	LA/AO (Heart Base; Swe)	FS (%)	EF (%)	EPSS (cm)
NORMAL PARAMETER	4.5-5.5	<2.7	1.3	<1.6	28-40	40-100	<0.6
PATIENT	NA	NA	NM	1.3	31	61	0.36
CANINE CARDIAC PARAMETERS	HR (BPM)	AV VMAX (m/s)	PV MAX (m/s)	BODY WEIGHT (kg)	LA 2D short axis Base view (cm)	LVIDd Avg; 2D and m-mode short axis (cm)	LVIDs Avg; 2D and m-mode short axis (cm)
NORMAL PARAMETER	50-100	0.7-1.7	0.7-1.6	BELOW	BELOW	BELOW	BELOW
PATIENT	NM	1.2	NM	12.4	2.3	2.6	1.8
*Normal chamber parameters expressed as a mean value (SD)							
BODY WEIGHT DEPENDENT PARAMETERS							
<i>*Note: All measurements based upon multi-modal images and methods. An average value is reported.</i>							
	3	1.27 (5.3)	2.46 (2.46)	1.36 (5.5)	5	1.40 (4.5)	2.74 (5.2)
	10	1.50 (3.8)	3.27 (3.5)	2.06 (3.1)	15	1.83 (2.0)	3.71 (2.4)
	20	2.02 (1.9)	4.14 (2.2)	2.80 (2.0)	25	2.18 (2.4)	4.48 (2.9)
	30	2.33 (3.3)	4.83 (3.9)	3.39 (3.4)	35	2.48 (4.3)	5.17 (5.0)
	40	2.62 (5.2)	5.48 (6.1)	3.96 (5.4)	50	2.88 (7.1)	6.07 (8.3)
	50	2.88 (7.1)	6.07 (8.3)	4.46 (7.4)			

Adapted from June Boon, Veterinary Echocardiography, 1998
Rishniw M and Hollis NE, J Vet Intern Med 2000; 14:429-435
Hansson et al, Vet Rad and Ultrasound 2002
Bonagura et al. Echocardiography: principles of interpretation, Vet Clin North Am 15:1177, 1995

HOSPITAL NAME

Eubank Animal Clinic

REFERRING VET

Dr. Solan

INVOICE

28627

DATE

1/30/23

INTERPRETATION OF THE FINDINGS & FURTHER RECOMMENDATIONS

Overtly normal cardiac structure and function with no cause of a murmur identified. No significant valvular insufficiencies were noted, and no structural issues identified. In the absence of significant volume changes (dehydration) or anemia, other possibilities include a physiologic



PATIENT

Sam Stiles

flow murmur only present with elevated heart rates, or a small flow abnormality not seen here. It is reasonable to monitor periodically via recheck echocardiography in the future, particularly should the murmur persist/progress. The ECG is unremarkable with a normal sinus rhythm.

SPECIES

Canine

No cardiac medications are indicated at this time. Monitor for any development of cough, labored breathing or exercise intolerance.

BREED

Beagle Mix

No cardiac contraindication for general anesthesia.

Recommend recheck echocardiogram in 12-18 months to screen for progression or development of concurrent cardiac disease that the preexisting murmur may mask.

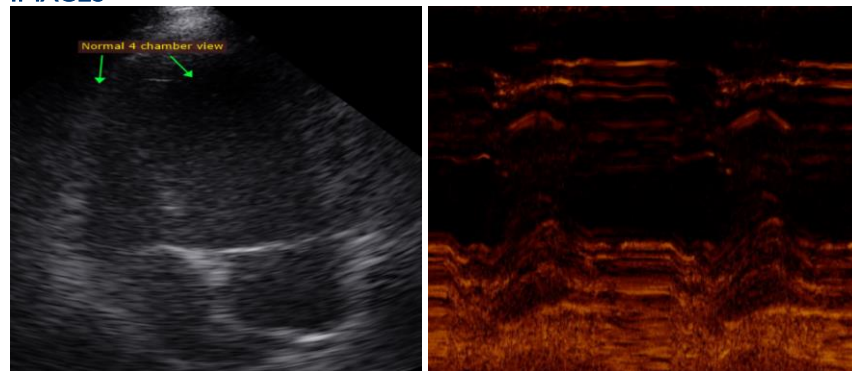
SEX

Male Neutered

IMAGES

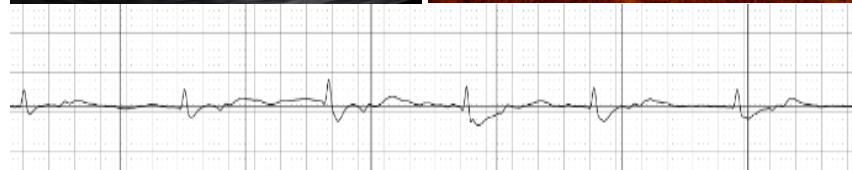
AGE

12 years



WEIGHT

27.4lbs



INTERPRETED BY

Maggie Machen Lamy,
DVM, DACVIM
(Cardiology)

The information and recommendations provided are based on the images presented by the referring veterinarian. No evaluation can be communicated regarding pathology that was not visible in the image/video clips provided.

IMAGING PERFORMED BY

Dana Alterman,
RDCS, LVT

Thank you for this referral. This report was generated using transcription software, and minor dictation errors may be present. If the clinical or image interpretation does not parallel your findings or if I can be of any further assistance, please contact me.

HOSPITAL NAME

Eubank Animal Clinic

Maggie Machen Lamy, DVM
Diplomate of the American College of Veterinary Internal Medicine (Cardiology)
info@sonopath.com

REFERRING VET

Dr. Solan

INVOICE

28627

DATE

1/30/23